

Venetoclax and Bortezomib in Relapsed/Refractory Early T-Cell Precursor Acute Lymphoblastic Leukemia

Roberta La Starza, MD, PhD¹; Benedetta Cambò, MD²; Antonio Pierini, MD, PhD¹; Beat Bornhauser, PhD³; Anna Montanaro²; Jean-Pierre Bourquin, MD, PhD³; Cristina Mecucci, MD, PhD¹; and Giovanni Roti, MD, PhD²

INTRODUCTION

Although in the past three decades we welcomed the advent of targeted therapies in several cancers, nelarabine, a purine nucleoside antimetabolite, remains the most recently approved drug to treat relapsed/refractory (R/R) T-cell acute lymphoblastic leukemia (T-ALL).^{1,2} Patients with R/R T-ALL experience a dramatic outcome, a situation that is more discouraging for the high-risk early T-cell precursor (ETP) ALL subtype.³ Historically, ETP ALL is associated with a worse prognosis in children and young adults compared with other T-ALL subtypes because of early resistance to chemotherapy.⁴⁻⁶ Although recent data suggest that allogeneic stem-cell transplantation in the first complete remission⁷ may overcome the poor prognosis associated with ETP ALL, novel biologic-based therapies are needed to improve the outcome in these patients. A strategy to overcome the current therapeutic limitations in rare leukemias may involve the development of functional precision medicine approaches on the basis of information by drug response profiling (DRP) of leukemia cells.⁸

CASE REPORT

Here we report our experience with a salvage treatment regimen that we designed on the basis of recurrent DRP patterns. We used a selection of 85 drugs in three patients with R/R ETP/near-ETP ALL after several lines of chemotherapy (Fig 1A).

Patient 1

A female patient (UPR1) presented at the hematology and bone marrow transplantation unit of the University of Parma at the age of 26 years with severe bone pain, fatigue, and dry cough unresponsive to over-the-counter analgesics. A WBC count revealed leukocytosis (51,430/cmm), anemia (Hb 9.9 g/dL), and thrombocytopenia (platelets 95,000/cmm). A chest computed tomography scan coupled with an ¹⁸F-labeled fluorodeoxyglucose–positron emission tomography scan identified a metabolically active lymphadenomegaly in the mediastinum. Flow cytometric analysis identified a bone marrow (BM) blast population (Fig 1A) that was negative for terminal deoxynucleotidyl transferase,

CD2, CD4, CD8, and CD1a and positive for human leukocyte antigen (HLA-DR), CD38, CD117, CD33, CD34, CD56, CD99, cyCD3, CD5, CD7, CD10, CD19, and CD13.

Because of a T-ALL immature phenotype^{9,10} and a myeloid interface, and despite CD5 expression, this patient was diagnosed with near-ETP ALL.¹¹ Molecular cytogenetic studies showed the presence of *DDX3X-MLL10* fusion gene derived from a three-way t(X;3;10)(p11;?;p13) translocation. Sanger sequencing detected *NOTCH1* and *NRAS* gain-of-function mutations (Fig 1A). The patient was treated with induction chemotherapy per the HyperCVAD protocol^{12,13} without response and reinduced per the GIMEMA LAL0904 regimen (ClinicalTrials.gov identifier: [NCT00458848](https://clinicaltrials.gov/ct2/show/study/NCT00458848)). A repeated CT scan and marrow examination 2 weeks after salvage chemotherapy showed persistent bulky disease and BM infiltration (47% of leukemic blasts).

Patient 2


A female patient (UPR2) presented at the hematology and BMT unit of the University of Parma at the age of 78 years with relapsed ETP ALL diagnosed 1 year before (Fig 1A). A WBC count showed leucopenia (1,380/cmm) with severe neutropenia, anemia (Hb 10 g/dL), and normal platelets (257,000/cmm). Molecular cytogenetic studies revealed an abnormal karyotype characterized by an isolated numerical abnormality (ie, 47,XX,+4[6]/46XX[4]), a rearrangement of *BCL11B*, and an internal tandem duplication of *FLT3* (Fig 1A). Because of advanced age and comorbidities, the patient was treated with prednisone 0.5 mg/kg and vincristine 1.4 mg/m² (days 1, 8, 15, and 22), without achieving hematologic remission. A cycle of nelarabine therapy at the reduced schedule of 750 mg/m² on days 1, 3, and 5 was administered, which led to a hematologic improvement for 1 year, when she presented at our hospital with neutropenia (neutrophils 840/cmm) and anemia (Hb 10 g/dL), with a re-expansion of the leukemic clone.

Patient 3

A male patient (UPG3) presented at the hematology unit of the University Hospital of Perugia with

Author affiliations and support information (if applicable) appear at the end of this article.

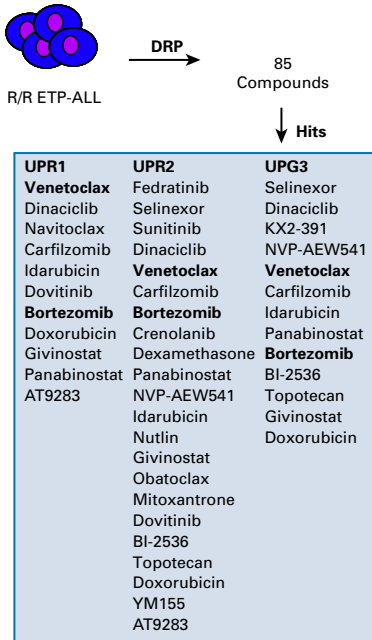
Accepted on August 16, 2019 and published at ascopubs.org/journal/po on September 20, 2019; DOI <https://doi.org/10.1200/P0.19.00172>

Licensed under the Creative Commons Attribution 4.0 License 

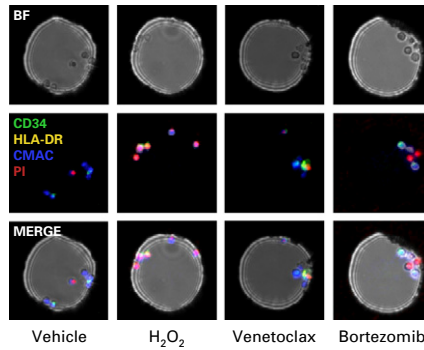
A

Patients	Sex/Age (years)	Immunophenotype	Extramedullary Disease	Gene Mutations	Cytogenetics	Group	Therapy
UPR1	F/26	HLA-DR ⁺ ; CD1a ⁺ ; CD2 ⁺ ; CD4 ⁺ ; CD8 ⁺ ; cyCD3 ⁺ ; CD5 ⁺ ; CD7 ⁺ ; CD13 ⁺ ; CD10 ⁺ ; CD19 ⁺ ; CD33 ⁺ ; CD34 ⁺ ; CD38 ⁺ ; CD56 ⁺ ; CD99 ⁺ ; CD117 ⁺ ; TdT ⁺	Spleen, liver, bulky mediastinum	<i>NOTCH1</i> c.5101 G>C, p.A1701P <i>NRAS</i> c.37G>T, p.G13C	46,X,t(X;3;10)(p?;p17;p13),add(19p)[2]/46,XX[19] <i>DDX3X-MLLT10</i> GAIN: 17q21.31-25.3	<i>HOXA</i>	HyperCVAD; GIMEMA LAL0904
UPR2	F/85	HLA-DR ⁺ ; CD2 ⁺ ; cyCD3 ⁺ ; CD5 ⁺ ; CD7 ⁺ ; CD13 ⁺ ; CD34 ⁺ ; CD38 ⁺ ; CD117 ⁺	No	<i>FLT3</i> -ITD	47,XX+4[6]/46,XX[4] <i>BCL11B</i> -translocation GAIN: 4p16.3-q35.2	Unclassified	Vincristine; nelarabine
UPG3	M/61	HLA-DR ^{+/−} ; CD1a [−] ; CD2 [−] ; CD3 [−] ; CD4 [−] ; CD8 [−] ; cyCD3 [−] ; CD5 ^{+/−} ; CD7 [−] ; CD13 ^{+/−} ; CD10 [−] ; CD19 [−] ; CD33 [−] ; CD34 ^{+/−} ; CD38 [−] ; CD56 [−] ; CD99 [−] ; CD117 [−] ; TdT ^{+/−}	Spleen, liver, lymph nodes	Wild type	46,XY[20] <i>ETV6/CDKN1B</i> ^{del} LOH: 2p25.2-21	Unclassified	HyperCVAD; NILG ALL 10/07; alemtuzumab

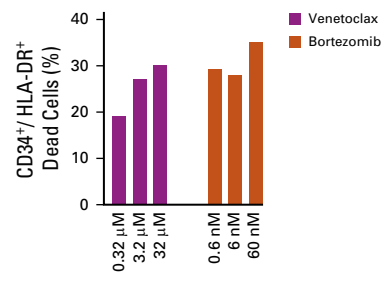
B



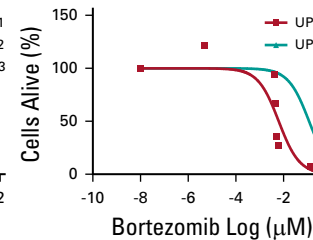
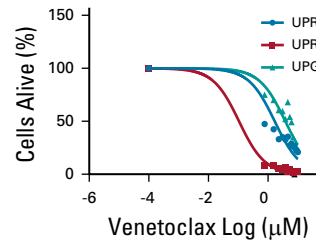
C



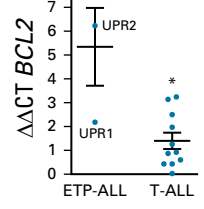
D



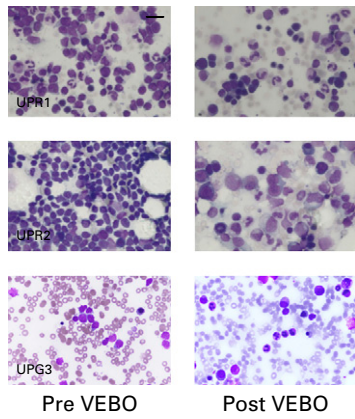
E



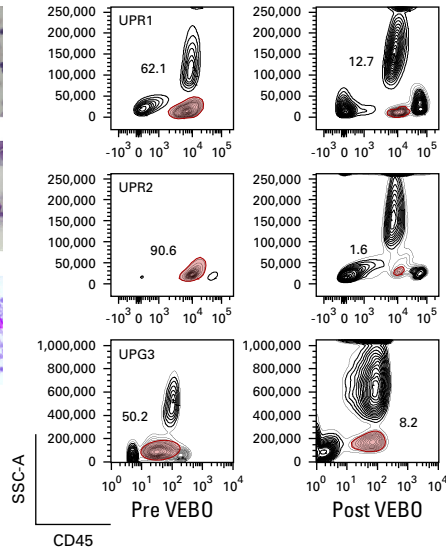
F



G



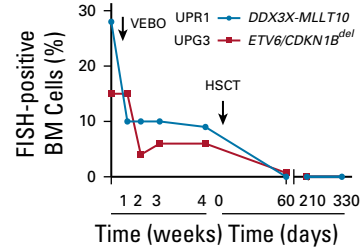
H



I

	UPR1	UPR2	UPG3
Days	+320	+56	+239
RBC	4010	3170	4720 ×10 ⁶ / uL
Hb	13.5	9.8	9.7 g/dL
MCV	99	91	103 fL
WBC	5030	3750	4720 ×10 ³ / uL
N	3280	2720	3870 ×10 ³ / uL
L	1280	540	425 ×10 ³ / uL
PLT	170	210	110 ×10 ³ / uL

J



Downloaded from ascopubs.org by University Degli Studi Di Parma on November 14, 2024 from 160.078.253.253
Copyright © 2024 American Society of Clinical Oncology. All rights reserved.

leucopenia (WBC 2,200/cmm), anemia (Hb 11 g/dL), and a moderate thrombocytopenia (platelets 115,000/cmm). Morphologic and flow cytometric analysis of BM cells (Fig 1A) showed a diffuse infiltration of lymphoid blasts negative for CD3, CD2, CD1a, CD8, CD4, CD33, CD117, CD56, and CD10 and positive for CD7, CD38, CD99, cCD3, deoxynucleotidyl transferase, CD34, CD13, CD5 (45%), and HLA-DR, consistent with a diagnosis of ETP ALL.¹⁰ Cytogenetics showed a normal diploid karyotype. Fluorescence in situ hybridization uncovered a cryptic deletion of the short arm of chromosome 12 involving *ETV6* and *CDKN1B* (Fig 1A). A CT/positron emission tomography scan showed metabolically active cells in the liver, spleen, and lymph nodes. The patient was treated with induction chemotherapy per the HyperCVAD protocol,^{12,13} which led to complete hematologic remission. Two months after the second HyperCVAD cycle, the disease relapsed and the patient was treated with chemotherapy per the Northern Italy Leukemia Group ALL 10/07 trial.¹⁴ A repeated marrow examination after 2 months showed persistent ETP ALL, and the patient was further treated with an anti-CD52 monoclonal antibody¹² for a cumulative dose of 100 mg, without benefit.

Because these cases were refractory to repeated standard induction therapy (UPR1, UPG3), or to salvage regimens (UPR2), we decided to support functional precision

medicine approaches to repurpose available therapeutic agents. Scoring the response in relation to data for T-ALL on a DRP platform,⁸ the B-cell lymphoma 2 (*BCL2*) inhibitor BH-3 mimetic venetoclax (ABT-199) and the proteasome inhibitor bortezomib ranked in all three cases among the most active drugs (Fig 1B). Next, we validated the activity of venetoclax and bortezomib using an open microwell microfluidic platform developed by CellPly¹⁵ (Bologna, Italy; Figs 1C and 1D) and an ATP-based cellular viability assay (Fig 1E) on ETP cells that, consistent with data reported in the literature,^{16,17} express a high level of *BCL2* (Fig 1AF).

On the basis of these findings, individualized treatment with venetoclax and bortezomib (VEBO) was then administered on an outpatient basis, sequentially or in combination, as off-label agents after approval by the relevant institutional review board. All patients received a cycle with venetoclax (800 mg per day × 28 days) by mouth and bortezomib (1.3 mg/m² twice a week × 2 [UPR1, UPR2] or × 4 [UPG3]), with no evidence of major toxicities. UPR1 and UPR2 received antiviral prophylaxis with acyclovir, whereas UPG3 received antimycotic treatment with micafungin. Patients obtained a hematologic complete (UPR2) or partial remission (UPR1 and UPG3) assessed a month after VEBO initial treatment quantified by morphology, flow cytometry analysis, and fluorescence in situ hybridization on bone marrow cells (Figs 1G and 1H). Age-eligible patients (UPR1

FIG 1. (A) Demographic, clinical, and genomic characteristics of the patients at baseline. Cytogenetic studies include karyotyping, fluorescence in situ hybridization (FISH), and single-nucleotide polymorphism array (question mark indicates undefined chromosome band). Sanger sequencing: *NOTCH1*, *FBXW7*, *PTEN*, *FLT3*, *N/K/H/RAS*, and *BRAF* hot-spot mutations. Immunophenotyping: +/- indicates 40% to 55% positive bone marrow (BM). (B) Identification of active molecules in patients with early T-cell precursor (ETP) acute lymphoblastic leukemia (ALL). ETP leukemia cells were profiled ex vivo with 85 small molecules. Dose-response curves were generated as previously published using five-point drug dilutions in duplicate.⁸ A ranked list of top hits was generated according to the criteria, Emax (ie, the % viability at the maximal drug concentration used) of less than 15% and significant ($P < .05$) difference of half maximal inhibitory concentration (IC50) value for each drug compared with the median IC50 for each particular drug in the reference data set.⁸ In bold: venetoclax and bortezomib (VEBO). (C) Effect of 24 hours of the vehicle (dimethyl sulfoxide), 10 mM hydrogen peroxide (H₂O₂), venetoclax, and bortezomib on cellular viability as measured by a functional profiling, on the basis of laboratory-on-a-chip technology, which allows testing the response of live tumor cells exposed to anticancer drugs in an automated process developed by CellPly. ETP ALL cells (eg, patient 2 [UPR2]) were labeled with a 7-amino-4-chloromethylcoumarin (CMAC) dye (blue), an anti-human antigen leukocyte (HLA-DR; green), and an anti-CD34 antibody (yellow) for leukemia cell identification. High-content time-lapsed imaging was performed for 24 hours, every 12 hours, on cells in 480 microwells (75 μm diameter) at a 1 px-1 μm resolution at each time point/condition tested. Cell death was quantified by imaging HLA-DR⁺CD34⁺ cells positive to the propidium iodide (PI) staining (red). Results are expressed as the percentage of PI⁺/HLA-DR⁺CD34⁺ positive cells relative to the negative population. (D) Results of C are depicted in the histograms. (E) Effect of venetoclax or bortezomib on cell viability after 72 hours of treatments in available ETP ALL cells as assessed by an ATP-based luminescence viability assay. Error bars denote ± standard deviation (SD) of two replicates. (F) Expression of *BCL2* in ETP ALL and non-ETP ALL (11 cases) as assessed by quantitative real-time polymerase chain reaction. Error bars indicate the mean ± SD of three replicates. Data were analyzed using the $\Delta\Delta$ CT method. (G) BM cytology at relapse (pre VEBO) and after completion of treatment with VEBO (post VEBO; May-Grünwald Giemsa staining at 63x). The marrow contains 50% (patient 1 [UPR1]), 90% (patient 2 [UPR2]), and 28% (patient 3 [UPG3]) of lymphoid blasts before treatment, which decreased rapidly after VEBO. A 500-cell count was performed based on examination of multiple fields to assess hematologic remission (complete remission indicates a blast percentage < 5% in the BM). (H) Antileukemia effect of VEBO treatment assessed by flow cytometry. CD45⁺ staining of primary ETP ALL cells at relapse and after one cycle of VEBO. A minimum of 20,000 events was collected for each condition. (I) Percentage of *DDX3X-MLLT10* (UPR1) and *ETV6/CDKN1B*^{del} (UPG3) FISH-positive BM cells during VEBO treatment and after an allogeneic hematopoietic stem-cell transplantation. The analysis was performed on 500 to 1,000 interphase nuclei for each experiment; the cutoff for *DDX3X-MLLT10* fusion was 2% and for *ETV6/CDKN1B*^{del} was 3%. UPR2 discontinued her BM follow-up after VEBO and retired to a hospice. (J) CBC count on the day of the last hematologic work-up. Days indicate the time elapsed from the last treatment (UPR1 and UPG3 from hematopoietic stem cell transplantation [HSCT], UPR2 from VEBO). BF, bright field; del, deletion; DRP, drug response profiling; Hb, hemoglobin; hyperCVAD, hyperfractionated cyclophosphamide, vincristine, doxorubicin, dexamethasone, and high-dose methotrexate and cytarabine; L, lymphocytes; MCV, mean corpuscular volume; N, neutrophils; NILG, Northern Italy Leukemia Group; PLT, platelets; R/R, relapsed/refractory; SSC-A, side scatter.

and UPG3) underwent an allogeneic stem-cell transplantation, achieving a stable cytogenetic remission (follow-up > 8 months; Fig 1J). All patients are off therapy and alive, with a progressive hematologic recovery (Fig 1I).

CONCLUSION

Although current chemotherapy regimens result in complete remission in 80% of adults with T-ALL, patients who do not achieve a complete remission or who have a primary resistant disease, including patients with ETP ALL, experience a dramatic poor prognosis.^{3,18} To this end, several groups seek to identify molecularly informed actionable targets¹⁹ or to develop therapeutic strategies to overcome chemotherapy resistance in T-ALL.²⁰ One approach is to develop small molecules on the basis of the identification of tumor dependencies conferred by specific genotypes. This is, for example, the case of γ -secretase inhibitors in *NOTCH1*-mutated T-ALL.²¹

An alternative option is to develop individualized approaches on the basis of pattern of responses to small molecule inhibitors.²² A first example was the development of a DRP in primary acute myeloid leukemia samples. The ex vivo testing of 187 drugs in 28 consecutive acute myeloid leukemia cases²² led to the identification of five major taxonomic drug-response subtypes with distinct genomic features. Importantly, therapies on the basis of DRP resulted in several clinical responses.²² More recently, Frismantas et al⁸ extended this idea and reported a proof-of-concept study by testing 60 drugs in 68 ALL cases. Selected single compounds and combinations were validated in xenograft models. This approach provided compelling evidence that differences in drug response can be pattern clustered in patient groups of interest and reveals patient-to-patient variation.⁸ For example, the authors identified a subset of patients with T-ALL without *ABL1* mutations or fusions responsive to dasatinib inhibition, suggesting an indirect mechanism of sensitivity to dasatinib-based therapy.⁸

Recently, two research groups independently reported that ETP ALL expresses high levels of BCL2 proteins compared with non-ETP ALL cases, resulting in enhanced susceptibility to Bcl2 suppression with BH-3 mimetics, such as

ABT-199.^{16,23} Venetoclax as a single agent has been shown to alter proliferation in human T-ALL cell lines and in primary samples, particularly those carrying an ETP phenotype.^{16,23} However, although venetoclax antitumor activity is promising, the rapid emergence of resistance may limit the use of this drug as a single agent.^{24,25} Thus, the downregulation of the antiapoptotic proteins BCL-XL or myeloid cell leukemia-1, which are not targeted by venetoclax, is a rational strategy. In support of this hypothesis, recent work demonstrated that bortezomib, a proteasome inhibitor, induces the BH3-only protein NOXA, which can then downregulate, among other Bcl-2 protein family members, myeloid cell leukemia-1.^{17,26} However, VEBO may go beyond R/R ETP ALL cases. Interestingly Li et al²⁷ demonstrated that venetoclax acts synergistically with the MCL1-specific inhibitor S63845 in a broad panel of T-ALL cell lines and in zebrafish embryos undergoing transplantation with T-ALL cells. Moreover, venetoclax showed clinical activity in patients with T-ALL both in combination with chemotherapy²⁸ or decitabine,²⁹ suggesting that it may be safely included in different therapeutic regimens.

In addition, bortezomib has recently emerged as a potential modulator of the oncogenic T-ALL driver *NOTCH1*. In fact, preclinical studies showed that bortezomib suppresses the expression of Notch and its target genes (*HES1*, *GATA3*, and *RUNX3*) and synergizes with dexamethasone, leading to a near-complete remission of T-ALL xenografted tumors in vivo,³⁰ supporting the rationale of several ongoing clinical trials (eg, ClinicalTrials.gov identifiers: [NCT02518750](#) and [NCT03643276](#)).

Our results illustrate the potential of functional drug profiling with the identification of an active regimen with less-toxic bioactive drugs for patients with highly resistant R/R T-ALL, and the basis for exploration of this principle for other leukemia subtypes. In conclusion, VEBO represents an effective and well-tolerated chemotherapy-free strategy for R/R T-ALL, including ETP especially, as a bridge to transplantation in fit patients.

AFFILIATIONS

¹Università degli Studi di Perugia, Perugia, Italy

²University of Parma, Parma, Italy

³University Children's Hospital Zurich, Zurich, Switzerland

CORRESPONDING AUTHOR

Giovanni Roti, MD, PhD, Università di Parma, Dipartimento di Medicina Clinica e Sperimentale, Via Gramsci 14, Parma, Emilia Romagna 43121, Italy; Twitter: @unipr.it; e-mail: giovanni.roti@unipr.it.

EQUAL CONTRIBUTION

R.L.S. and B.C. are co-first authors.

SUPPORT

This work was supported by Fondazione AIRC per la Ricerca sul Cancro Start-up Investigator Grant No. 17107 (G.R.), Fondazione Cariparma Grants No. 3576/2017 and 0180/2018 (G.R.), Fondazione Grande Ale Onlus (G.R.), Fondazione Cassa di Risparmio di Perugia project code No. 2018.04818.021 ricerca scientifica e tecnologica, and Progetti di Rilevante Interesse Nazionale 2017 Grant No. 2017PPS2X4 (C.M.).

AUTHOR CONTRIBUTIONS

Conception and design: All authors

Financial support: Beat Bornhauser, Giovanni Roti

Provision of study material or patients: Benedetta Cambò, Beat Bornhauser

Collection and assembly of data: Roberta La Starza, Benedetta Cambò, Antonio Pierini, Anna Montanaro, Jean-Pierre Bourquin, Cristina Mecucci

Data analysis and interpretation: Roberta La Starza, Benedetta Cambò, Antonio Pierini, Beat Bornhauser, Anna Montanaro, Jean-Pierre Bourquin, Cristina Mecucci

Manuscript writing: All authors

Final approval of manuscript: All authors

AUTHORS' DISCLOSURES OF POTENTIAL CONFLICTS OF INTEREST

The following represents disclosure information provided by authors of this manuscript. All relationships are considered compensated. Relationships

are self-held unless noted. I = Immediate Family Member, Inst = My Institution. Relationships may not relate to the subject matter of this manuscript. For more information about ASCO's conflict of interest policy, please refer to www.asco.org/rwc or ascopubs.org/po/author-center.

Antonio Pierini

Consulting or Advisory Role: Pfizer, Biotest

Patents, Royalties, Other Intellectual Property: Antibody to deliver cells for islet engraftment in diabetes

Jean-Pierre Bourquin

Travel, Accommodations, Expenses: Servier, Amgen

Cristina Mecucci

Patents, Royalties, Other Intellectual Property: Patent on NPM1 mutations in acute myeloid leukemia with normal karyotype

No other potential conflicts of interest were reported.

REFERENCES

- DeAngelo DJ, Yu D, Johnson JL, et al: Nelarabine induces complete remissions in adults with relapsed or refractory T-lineage acute lymphoblastic leukemia or lymphoblastic lymphoma: Cancer and Leukemia Group B study 19801. *Blood* 109:5136-5142, 2007
- Bassan R, Bourquin JP, DeAngelo DJ, et al: New approaches to the management of adult acute lymphoblastic leukemia. *J Clin Oncol* 10.1200/JCO.2017.77.3648 [epub ahead of print on September 21, 2018]
- Litzow MR, Ferrando AA: How I treat T-cell acute lymphoblastic leukemia in adults. *Blood* 126:833-841, 2015
- Inukai T, Kiyokawa N, Campana D, et al: Clinical significance of early T-cell precursor acute lymphoblastic leukaemia: Results of the Tokyo Children's Cancer Study Group Study L99-15. *Br J Haematol* 156:358-365, 2012
- Ma M, Wang X, Tang J, et al: Early T-cell precursor leukemia: A subtype of high risk childhood acute lymphoblastic leukemia. *Front Med* 6:416-420, 2012
- Jain N, Lamb AV, O'Brien S, et al: Early T-cell precursor acute lymphoblastic leukemia/lymphoma (ETP-ALL/LBL) in adolescents and adults: A high-risk subtype. *Blood* 127:1863-1869, 2016
- Brammer JE, Saliba RM, Jorgensen JL, et al: Multi-center analysis of the effect of T-cell acute lymphoblastic leukemia subtype and minimal residual disease on allogeneic stem cell transplantation outcomes. *Bone Marrow Transplant* 52:20-27, 2017
- Frismantas V, Dobay MP, Rinaldi A, et al: Ex vivo drug response profiling detects recurrent sensitivity patterns in drug-resistant acute lymphoblastic leukemia. *Blood* 129:e26-e37, 2017
- Chopra A, Bakhshi S, Pramanik SK, et al: Immunophenotypic analysis of T-acute lymphoblastic leukemia. A CD5-based ETP-ALL perspective of non-ETP T-ALL. *Eur J Haematol* 92:211-218, 2014
- Coustan-Smith E, Mullighan CG, Onciu M, et al: Early T-cell precursor leukaemia: A subtype of very high-risk acute lymphoblastic leukaemia. *Lancet Oncol* 10:147-156, 2009
- Liu Y, Easton J, Shao Y, et al: The genomic landscape of pediatric and young adult T-lineage acute lymphoblastic leukemia. *Nat Genet* 49:1211-1218, 2017
- Murphy SB, Bowman WP, Abromowitch M, et al: Results of treatment of advanced-stage Burkitt's lymphoma and B cell (Slg+) acute lymphoblastic leukemia with high-dose fractionated cyclophosphamide and coordinated high-dose methotrexate and cytarabine. *J Clin Oncol* 4:1732-1739, 1986
- Kantarjian H, Thomas D, O'Brien S, et al: Long-term follow-up results of hyperfractionated cyclophosphamide, vincristine, doxorubicin, and dexamethasone (Hyper-CVAD), a dose-intensive regimen, in adult acute lymphocytic leukemia. *Cancer* 101:2788-2801, 2004
- Bassan R, Masciulli A, Intermesoli T, et al: Final results of Northern Italy Leukemia Group (NILG) trial 10/07 combining pediatric-type therapy with minimal residual disease study and risk-oriented hematopoietic cell transplantation in adult acute lymphoblastic leukemia (ALL). *Blood* 128:176, 2016
- Rocchi L, Faenza A, Rambelli L, et al: Ex-vivo drug response profiling for precision medicine approaches in acute myeloid leukemia with the open microwell microfluidic platform. *Blood* 128:1675, 2016
- Peirs S, Matthijssens F, Goossens S, et al: ABT-199 mediated inhibition of BCL-2 as a novel therapeutic strategy in T-cell acute lymphoblastic leukemia. *Blood* 124:3738-3747, 2014
- Punnoose EA, Levenson JD, Peale F, et al: Expression profile of BCL-2, BCL-XL, and MCL-1 predicts pharmacological response to the BCL-2 selective antagonist venetoclax in multiple myeloma models. *Mol Cancer Ther* 15:1132-1144, 2016
- Marks DI, Paietta EM, Moorman AV, et al: T-cell acute lymphoblastic leukemia in adults: Clinical features, immunophenotype, cytogenetics, and outcome from the large randomized prospective trial (UKALL XII/ECOG 2993). *Blood* 114:5136-5145, 2009
- Roti G, Stegmaier K: New approaches to target T-ALL. *Front Oncol* 4:170, 2014
- Follini E, Marchesini M, Roti G: Strategies to overcome resistance mechanisms in T-cell acute lymphoblastic leukemia. *Int J Mol Sci* 20:E3021, 2019
- Roti G, Stegmaier K: Targeting NOTCH1 in hematopoietic malignancy. *Crit Rev Oncog* 16:103-115, 2011
- Pemovska T, Kontro M, Yadav B, et al: Individualized systems medicine strategy to tailor treatments for patients with chemorefractory acute myeloid leukemia. *Cancer Discov* 3:1416-1429, 2013
- Chonghaile TN, Roderick JE, Glenfield C, et al: Maturation stage of T-cell acute lymphoblastic leukemia determines BCL-2 versus BCL-XL dependence and sensitivity to ABT-199. *Cancer Discov* 4:1074-1087, 2014
- Bose P, Gandhi V, Konopleva M: Pathways and mechanisms of venetoclax resistance. *Leuk Lymphoma* 58:1-17, 2017
- Tahir SK, Smith ML, Hessler P, et al: Potential mechanisms of resistance to venetoclax and strategies to circumvent it. *BMC Cancer* 17:399, 2017

26. Qin JZ, Ziffra J, Stennett L, et al: Proteasome inhibitors trigger NOXA-mediated apoptosis in melanoma and myeloma cells. *Cancer Res* 65:6282-6293, 2005
27. Li Z, He S, Look AT: The MCL1-specific inhibitor S63845 acts synergistically with venetoclax/ABT-199 to induce apoptosis in T-cell acute lymphoblastic leukemia cells. *Leukemia* 33:262-266, 2019
28. Numan Y, Alfayez M, Maiti A, et al: First report of clinical response to venetoclax in early T-cell precursor acute lymphoblastic leukemia. *JCO Precis Oncol* [10.1200/PO.18.00127](https://doi.org/10.1200/PO.18.00127)
29. Rahmat LT, Nguyen A, Abdulhaq H, et al: Venetoclax in combination with decitabine for relapsed T-cell acute lymphoblastic leukemia after allogeneic hematopoietic cell transplant. *Case Rep Hematol* [10.1155/2018/6092646](https://doi.org/10.1155/2018/6092646)
30. Koyama D, Kikuchi J, Hiraoka N, et al: Proteasome inhibitors exert cytotoxicity and increase chemosensitivity via transcriptional repression of Notch1 in T-cell acute lymphoblastic leukemia. *Leukemia* 28:1216-1226, 2014

